

Case Report

# Long-Term 5-Year Response to Pembrolizumab, Bevacizumab, and Capecitabine Regimen in a Metastatic Colon Cancer Patient with MSI-High and KRAS Mutation: Case Report

Pramod Kumar Julka<sup>a</sup> Deepika Arya<sup>a</sup> Kush Gupta<sup>b</sup>

<sup>a</sup>Department of Medical Oncology, Max Institute of Cancer Care, Delhi, India; <sup>b</sup>Department of Clinical Operations, Catalyst Clinical Services Pvt. Ltd., Delhi, India

## Keywords

Pembrolizumab · Bevacizumab · Capecitabine · Metastatic colon cancer · MSI-high

## Abstract

With an estimated 1.88 million new cases and 0.92 million deaths in 2020, colorectal cancer accounts for nearly one-tenth of all new cancer and cancer-related deaths worldwide. Nearly half of the patients of colorectal cancer are diagnosed with metastatic or inoperable disease with a very dismal 5-year survival rate. Chemotherapy, targeted therapy, and immunotherapy have been used to treat metastatic disease, either alone or in combination. We present a case of recurrent metastatic colon carcinoma with KRAS exon 2 mutation and high microsatellite instability that was treated with a combination regimen of bevacizumab, capecitabine oral chemotherapy, and pembrolizumab immunotherapy. At nearly 5 years of treatment, the patient is alive with good performance status and improved quality of life owing to a favorable response to the molecular profiling-based treatment approach.

© 2023 The Author(s).  
Published by S. Karger AG, Basel

## Introduction

Colorectal cancer (CRC) ranks third among the most common cancers and second among the leading causes of cancer death in the world [1]. The treatment for advanced disease continues to be based on surgery followed by adjuvant chemotherapy. However, nearly 50%

Correspondence to:  
Pramod Kumar Julka, pkjulka18@yahoo.co.in

of patients have metastatic or inoperable disease at the time of diagnosis or develop the same during treatment, with a very dismal 5-year survival rate of  $\leq 5\%$  [2]. Previous studies have shown that compared to fluoropyrimidine monotherapy, a combination of chemotherapy such as FOLFOX triplet (folinic acid + 5-fluorouracil + oxaliplatin), FOLFIRI triplet (folinic acid + 5-fluorouracil + irinotecan), and CAPOX doublet (capecitabine + oxaliplatin) significantly prolongs progression-free survival (PFS) and overall survival (OS) for patients with advanced disease, establishing them as a standard first-line treatment [3–5]. In a randomized phase III trial of FOLFIRI versus FOLFOX, there was no difference in the response rate (RR), time to progression, and OS in patients who had not previously been treated for advanced CRC [4]. Oral administration of fluoropyrimidine capecitabine clearly offsets the limitation of prolonged infusion required by the FOLFOX regimen. While the CAPOX regimen has shown non-inferiority to the FOLFOX regimen in the first-line treatment for metastatic CRC (mCRC), the two regimens have not been compared in adjuvant settings.

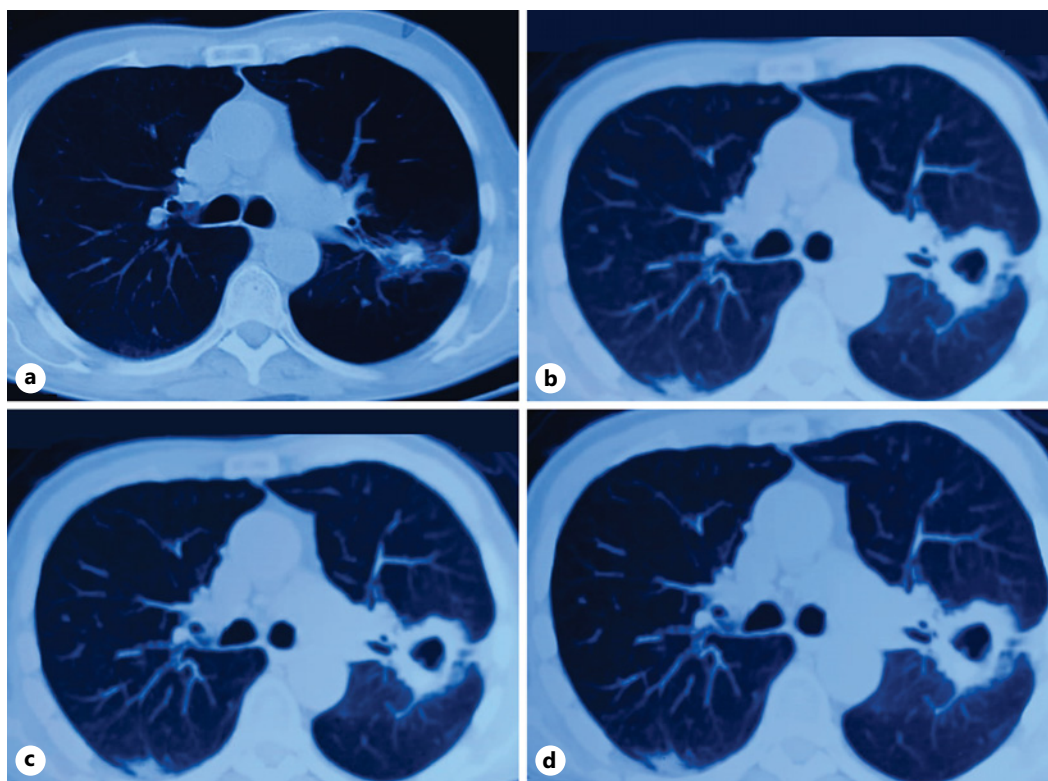
In the mid-aughts, biological therapies in the form of bevacizumab, a recombinant humanized monoclonal antibody against vascular endothelial growth factor (VEGF), have added the survival benefits to chemotherapy alone as a first-line treatment for mCRC [6, 7]. Ramucirumab and aflibercept are the other approved VEGF inhibitors for the second-line treatment of mCRC. The survival benefits of regorafenib, an oral multi-kinase inhibitor, have led to its approval as salvage therapy. However, treatment with regorafenib at the recommended dose is linked to a significant increase in adverse event-related, dose interruptions, dose reductions, and permanent discontinuation in a vulnerable population of pre-treated patients with advanced cancer. Based on this finding, personalized strategies are suggested to maximize the treatment benefits of regorafenib [8]. For wild-type, KRAS, and NRAS tumors, monoclonal antibodies against the epidermal growth factor receptor (EGFR), such as cetuximab and panitumumab, have demonstrated their effectiveness as monotherapy. In a phase III randomized trial, the RR and median time to progression were significantly higher in the cetuximab and irinotecan group (22.9% vs. 10.8%,  $p = 0.007$  and 4.1 vs. 1.5 months,  $p < 0.001$ ) than in the cetuximab group alone [9]. Similarly, the use of panitumumab and best supportive care resulted in a significant improvement in PFS compared to best supportive care alone in patients with chemotherapy-refractory mCRC. The analysis of the CALGB/SWOG 80405 study [10] showed that the OS in tumors on the left-sided is almost three times higher than in tumors on the right side (39.3 vs. 13.6 months) in the RAS wild-type. In left-side tumors, cetuximab had a longer survival time than bevacizumab (36 vs. 31.4 months), while in right-side tumors, bevacizumab had a longer survival time than cetuximab (24.2 vs. 16.7 months). Deficient DNA mismatch repair (*dMMR*) genes associated with tumors with high microsatellite instability (MSI-H) are known to present a strong immunogenic response and provide a better prognosis. Immunotherapy with PD-1 inhibitors has shown extremely encouraging results in about 3–6% of advanced CRC patients with MSI-H or *dMMR* genes. To date, two immune checkpoint inhibitors namely pembrolizumab and nivolumab which target PD-1 have been approved for MSI-H and *dMMR* advanced CRC patients who have failed the first-line chemotherapy [11, 12]. Here, we report a case of a metastatic colon cancer patient with MSI-H and KRAS mutation who was treated with bevacizumab, capecitabine, and pembrolizumab combination therapy.

### Case Presentation

A 75-year-old, nondiabetic, non-hypertensive male was diagnosed with a stage III (T3N1) transverse colon carcinoma, in November 2011. He had open surgery, an extended right colectomy, with an ileo-transverse anastomosis and the histopathological

findings indicated a moderately differentiated adenocarcinoma colon with lymphovascular invasion. He received 6 months of adjuvant chemotherapy with CAPOX from January to June 2012. During the follow-up, the contrast-enhanced computerized tomography abdomen done in June 2012 and the colonoscopy done in November 2012 were found to be normal. In December 2014, positron emission tomography-computed tomography (PET-CT) revealed a nodule in the apico-posterior segment of the left upper lobe of the lung (14 × 10 mm) with several FDG avid mesenteric lymph nodes and non-FDG avid subcapsular hypodensity in segment VIII of the liver. The patient did not agree to the invasive procedure and continued diagnostic follow-up with PET-CT. Later in June 2016, PET-CT showed an interval progression of the lung lesion with stable liver lesions. The patient underwent a VATS resection of the lesion, segmentectomy of the left upper lobe, and histopathological results revealed metastatic adenocarcinoma with immunohistochemistry suggestive of gastrointestinal origin. This was followed by 8 cycles of CAPOX (oxaliplatin 130 mg/m<sup>2</sup> day 1 and capecitabine 1,000 mg/m<sup>2</sup> day 1–14, q 3 weekly) between August 2016 and January 2017. PET-CT after 8 cycles of CAPOX showed postoperative changes without any metabolically active lesions anywhere, suggesting local recurrence or distant metastasis. PET-CT done in July 2017 showed a recurrence with FDG avid nodular opacity adjacent to the fibrotic band and the surgical suture. The patient declined an FNAC/biopsy and received stereotactic body radiation therapy for the lung lesion in September 2017. Later in November 2017, PET-CT showed a few mildly FDG avid right common iliac lymph nodes along with stable lung nodule. Due to the progression of the disease and the need for alternate systemic therapy, a mutational analysis was conducted on the tissues from the right common iliac vessels using next-generation sequencing. Although KRAS exon 2 mutation was present, BRAF and NRAS were not detected.

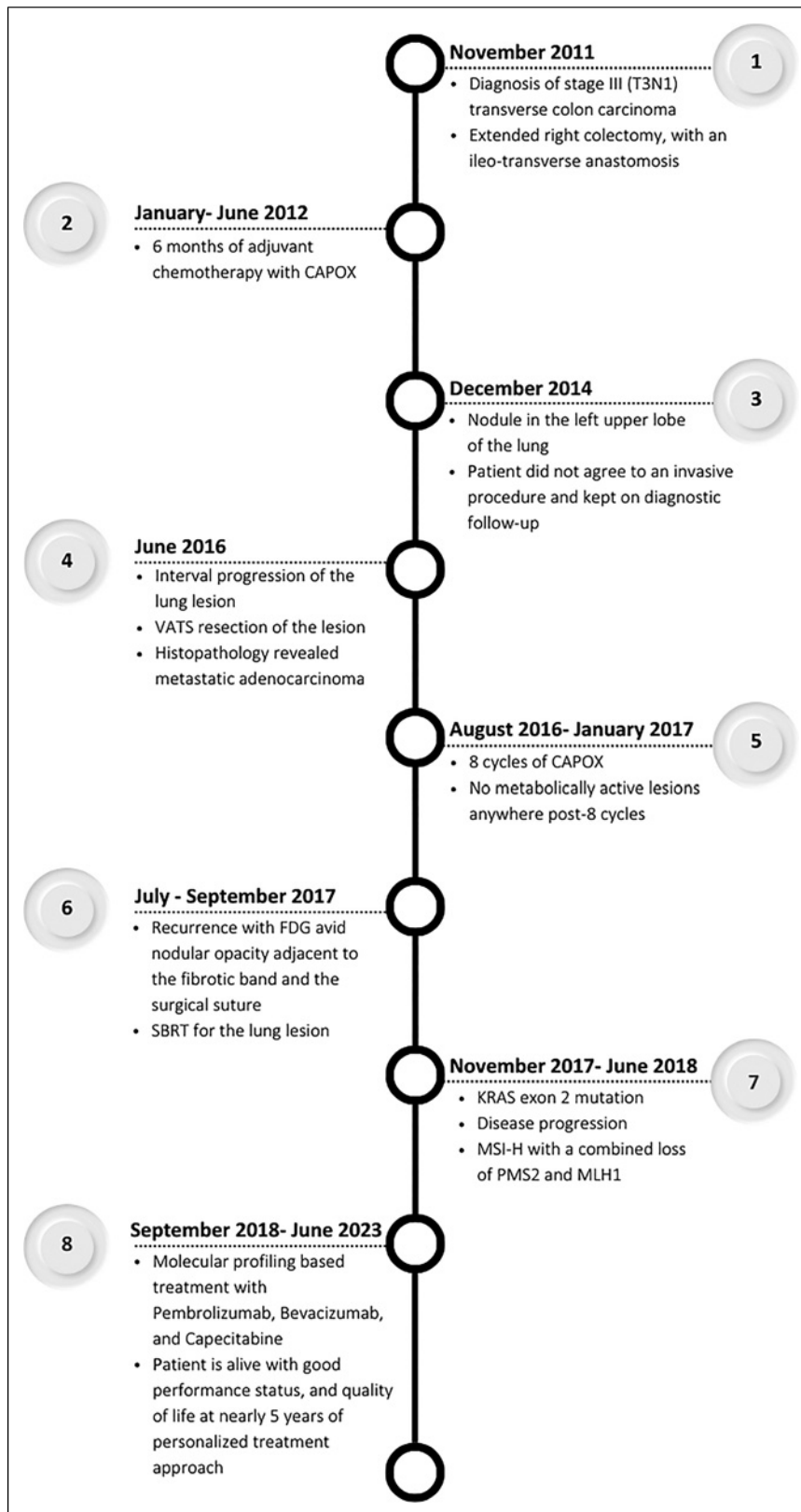
The patient failed to show up for the next 6 months and came to see us in June 2018 with complaints of ongoing significant weight loss, severe fatigue, and the Eastern Cooperative Oncology Group (ECOG) performance status (PS) of 2. The PET-CT showed a progression of the disease (Fig. 1a). Microsatellite instability screening on the biopsy blocks showed MSI-H with a combined loss of PMS2 and MLH1 (defective mismatch repair). Based on the molecular profiling and clinical judgment a choice of combination therapy was made and the patient was started on pembrolizumab (200 mg, q 3 weekly), bevacizumab (10 mg/kg, q 3 weekly), and capecitabine (1,000 mg twice daily × 14 days) in September 2018. A stable disease was revealed by periodic PET-CT scans carried out after the initiation of combination therapy. Patient weight was maintained, fatigue improved and the ECOG PS also improved to 1. The patient remained on a stable disease for 18 months, and the PET-CT in March 2020 showed an unconfirmed progressive disease according to iRECIST criteria. The patient continued with the planned treatment and the same medical condition was maintained for the following 40 months. Due to recurrent loose stools and stable disease status, capecitabine was discontinued in April 2023, but the patient continued to take pembrolizumab and bevacizumab. After 75 cycles up until June 2023, the patient remained in residual metabolic disease status with no new lesions (Fig. 1b–d). The patient is alive with good PS, and quality of life after nearly 5 years of personalized treatment approach based on molecular profiling. The patient maintains clinical benefits with an ECOG PS of 1, a stable weight, and no significant fatigue or any other adverse drug reaction. Figure 2 depicts a timeline that summarizes the main events of the case. The CARE Checklist has been completed by the authors for this case report and is attached as online supplementary material (for all online suppl. material, see <https://doi.org/10.1159/000533760>).



**Fig. 1.** PET CT images taken at different time points. **(a)** Lung nodule after 10 months of SBRT and prior to initiation of personalized treatment regimen in August 2018; **(b)** lung nodule with cavitation and surrounding fibrosis likely to be RT induced in September 2020; **(c)** lung nodule with cavitation and surrounding fibrosis in May 2022; and **(d)** lung nodule with cavitation and surrounding fibrosis in June 2023. SBRT, stereotactic body radiation therapy.

## Discussion

Several studies have shown that mCRC harboring KRAS mutations are associated with a lack of response to the anti-EGFR treatment of monoclonal antibodies [13, 14]. Furthermore, KRAS upregulates VEGF and other angiogenic factors in tumor cells which supports the role of anti-VEGF agents in treating these patients [15]. The combination of bevacizumab with 5-fluorouracil/leucovorin or FOLFOX or FOLFIRI regimens has shown superior efficacy in the first- and second-line settings [7]. Studies have also shown that continuation of bevacizumab beyond disease progression is associated with clinical benefits in mCRC patients [16]. Capecitabine monotherapy has demonstrated some success in stabilizing the disease in patients with mCRC refractory to 5-Fluorouracil/leucovorin chemotherapy [17]. However, a randomized phase III trial has shown that the addition of bevacizumab to capecitabine, with or without mitomycin, significantly improves PFS (8.5 months vs. 5.7 months, hazard ratio, 0.63; 95% CI, 0.50–0.79;  $p < 0.001$ ) without additional toxicity in previously untreated, unresectable mCRC patients [18]. Similarly, another phase III trial in elderly patients ( $\geq 70$  years) of mCRC has shown that the median PFS was significantly longer in the bevacizumab plus capecitabine group (9.1 vs. 5.1 months, hazard ratio, 0.53; 95% CI, 0.41–0.69,  $p < 0.0001$ ) than in capecitabine alone [19]. Furthermore, the combination of bevacizumab and capecitabine was well tolerated with a longer OS (20.7 vs. 16.8 months, hazard ratio, 0.79; 95% CI, 0.57–1.09). Given that our patient was also an elderly patient with a right-sided tumor and a KRAS exon 2 mutation, we decided to include bevacizumab and capecitabine in the treatment regimen.



**Fig. 2.** A timeline that summarizes the main events of the case.

dMMR status has been shown to have prognostic implications in patients with CRC. The two major trials, KEYNOTE 028 and CheckMate 142 resulted in the FDA approval of pembrolizumab and nivolumab in mCRC patients with dMMR and/or MSI-H [11, 12]. The phase II, KEYNOTE 028 study reported a higher immune-related overall RR (40% vs. 0%), PFS (78% vs. 11%), and disease control rate over 12 weeks (90% vs. 11%) with pembrolizumab (10 mg/kg, every 14 days), for dMMR as compared to mismatch repair-proficient (pMMR) mCRC patients [11]. On May 23, 2017, the FDA granted site agnostic approval to pembrolizumab for the treatment of patients with unresectable or metastatic, MSI-H, or dMMR solid tumors who have progressed following prior treatment and do not have satisfactory alternative treatment options. This approval was based on the results of a pooled analysis of 5 clinical trials namely KEYNOTE 012, 028, 016, 158, and 164 involving 149 patients from 14 different types of cancer, nearly 60% of whom had mCRC [20]. The analysis revealed an ORR of 39.6% (95% CI, 31.7–47.9), a complete RR of 7%, and a duration of response ranging from 1.6 to 22.7 months with 78% of responses lasting for more than 6 months. Presently, the role of immunotherapy in mCRC is restricted to MSI-H and dMMR-expressing tumors that are refractory to chemotherapy.

Considering the promising results of these studies and the MSI-H status, which indicates potential sensitivity to immune checkpoint inhibitors, a personalized treatment strategy was implemented for our patient. The patient was started on a combination regimen of bevacizumab, capecitabine, and pembrolizumab due to the KRAS exon 2 mutations, which are known to confer resistance to anti-EGFR therapies, and the presence of MSI-H. To the best of our knowledge, not a single case has been reported in the literature to date to treat mCRC using this combination. However, a phase II study (NCT03396926) in the second-line setting is currently underway to evaluate this regimen for treating patients with microsatellite stable CRC that is locally advanced, metastatic, or cannot be removed by surgery [21]. The positive outcome in our patient may be due to his male sex, as previous studies have found sex-related variations in immunotherapy response. The MOUSEION-01 study, which assessed the influence of sex-related variations on immunotherapy response in cancer patients, found a slight difference in antitumor efficacy between male and female patients [22]. The MOUSEION-03 research looked at the chances of cancer patients experiencing complete remissions after receiving immunotherapy. A total of 49,425 cancer patients from 85 randomized trials were included in this meta-analysis. The results of the study indicated that, in comparison to control treatment, the use of immune checkpoint inhibitors may significantly increase the chance of achieving complete remissions [23]. Due to his metastatic disease, we were unable to achieve a complete remission for our patient but we did manage to keep his condition stable for a very long period. This case shows that a personalized treatment approach based on molecular profiling can lead to a favorable treatment response in metastatic colon cancer. The patient is alive with good PS at nearly 5 years of follow-up which is well beyond the previously published reports. Furthermore, this case demonstrates the clinical utility of pembrolizumab, capecitabine, and bevacizumab combination therapy for treating KRAS mutated, and MSI-H, metastatic colon cancers.

## Conclusion

The management of mCRC continues to be a major health concern worldwide. New targeted, and immunotherapies have improved RR, PFS, and OS, but the 5-year survival rate is still very dismal. In patients with recurrent mCRC, KRAS mutation testing, and MSI status assessment are crucial in guiding treatment decisions. A personalized treatment approach

based on molecular profiling followed by treatment with a combination regimen holds the promise of achieving improved survival outcomes in a subset of patients whose tumors harbor targetable mutations.

### Statement of Ethics

Ethical approval is not required for this study in accordance with local or national guidelines. Written informed consent was obtained from the patient for publication of the details of their medical case and any accompanying images.

### Conflict of Interest Statement

The authors report no conflicts of interest in this work. No benefits in any form have been received or will be received from a commercial party related directly or indirectly to the subject of this article.

### Funding Sources

The author(s) received no financial support for the research, authorship, and/or publication of this article.

### Author Contributions

P.K.J. was responsible for designing the treatment plan, patient management, data collection, analysis, and paper writing. D.A. was responsible for patient management and data collection. K.G. was responsible for data analysis and paper writing. P.K.J., D.A., and K.G. were responsible for reviewing the paper before the final submission. All authors have read and approved the manuscript.

### Data Availability Statement

All data generated or analyzed during this study are included in this article and its online supplementary material. Further inquiries can be directed to the corresponding author.

### References

- 1 Morgan E, Arnold M, Gini A, Lorenzoni V, Cabasag CJ, Laversanne M, et al. Global burden of colorectal cancer in 2020 and 2040: incidence and mortality estimates from GLOBOCAN. *Gut*. 2023 Feb;72(2):338–44.
- 2 Meta-analysis Group In Cancer; Piedbois P, Rougier P, Buyse M, Pignon J, Ryan L, et al. Efficacy of intravenous continuous infusion of fluorouracil compared with bolus administration in advanced colorectal cancer. *J Clin Oncol*. 1998 Jan;16(1):301–8.
- 3 Twelves C, Scheithauer W, McKendrick J, Seitz JF, Van Hazel G, Wong A, et al. Capecitabine versus 5-fluorouracil/folinic acid as adjuvant therapy for stage III colon cancer: final results from the X-ACT trial with analysis by age and preliminary evidence of a pharmacodynamic marker of efficacy. *Ann Oncol*. 2012 May;23(5):1190–7.

- 4 Colucci G, Gebbia V, Paoletti G, Giuliani F, Caruso M, Gebbia N, et al. Phase III randomized trial of FOLFIRI versus FOLFOX4 in the treatment of advanced colorectal cancer: a multicenter study of the Gruppo Oncologico Dell'Italia Meridionale. *J Clin Oncol*. 2005 Aug 1;23(22):4866–75.
- 5 Simmonds PC. Palliative chemotherapy for advanced colorectal cancer: systematic review and meta-analysis. Colorectal Cancer Collaborative Group. *BMJ*. 2000 Sep 2;321(7260):531–5.
- 6 Grothey A, Marshall JL. Optimizing palliative treatment of metastatic colorectal cancer in the era of biologic therapy. *Oncology*. 2007 Apr;21(5):553–64, 566; discussion 566–8, 577–8.
- 7 Hurwitz H, Fehrenbacher L, Novotny W, Cartwright T, Hainsworth J, Heim W, et al. Bevacizumab plus irinotecan, fluorouracil, and leucovorin for metastatic colorectal cancer. *N Engl J Med*. 2004 Jun 3;350(23):2335–42.
- 8 Rizzo A, Nannini M, Novelli M, Dalia Ricci A, Scioscio VD, Pantaleo MA. Dose reduction and discontinuation of standard-dose regorafenib associated with adverse drug events in cancer patients: a systematic review and meta-analysis. *Ther Adv Med Oncol*. 2020 Jul 7;12:1758835920936932.
- 9 Cunningham D, Humblet Y, Siena S, Khayat D, Bleiberg H, Santoro A, et al. Cetuximab monotherapy and cetuximab plus irinotecan in irinotecan-refractory metastatic colorectal cancer. *N Engl J Med*. 2004 Jul 22;351(4):337–45.
- 10 Venook AP, Niedzwiecki D, Innocenti F, Fruth B, Greene C, O'Neil BH, et al. Impact of primary (1°) tumor location on overall survival (OS) and progression-free survival (PFS) in patients (pts) with metastatic colorectal cancer (mCRC): analysis of CALGB/SWOG 80405 (Alliance). *J Clin Oncol*. 2016;34(15 Suppl):3504.
- 11 Le DT, Uram JN, Wang H, Bartlett BR, Kemberling H, Eyring AD, et al. PD-1 blockade in tumors with mismatch-repair deficiency. *N Engl J Med*. 2015 Jun 25;372(26):2509–20.
- 12 Overman MJ, McDermott R, Leach JL, Lonardi S, Lenz HJ, Morse MA, et al. Nivolumab in patients with metastatic DNA mismatch repair-deficient or microsatellite instability-high colorectal cancer (CheckMate 142): an open-label, multicentre, phase 2 study. *Lancet Oncol*. 2017 Sep;18(9):1182–91.
- 13 Van Cutsem E, Lang I, D'haens G, Moiseyenko V, Zaluski J, Folprecht G, et al. KRAS status and efficacy in the first-line treatment of patients with metastatic colorectal cancer (mCRC) treated with FOLFIRI with or without cetuximab: the CRYSTAL experience. *J Clin Oncol*. 2008 May 20;26(15 Suppl):2.
- 14 Punt CJ, Tol J, Rodenburg CJ, Cats A, Creemers G, Schrama JG, et al. Randomized phase III study of capecitabine, oxaliplatin, and bevacizumab with or without cetuximab in advanced colorectal cancer (ACC), the CAIRO2 study of the Dutch Colorectal Cancer Group (DCCG). *J Clin Oncol*. 2008 May 20;26(15 Suppl):LBA4011.
- 15 Downward J. Targeting RAS signalling pathways in cancer therapy. *Nat Rev Cancer*. 2003 Jan;3(1):11–22.
- 16 Koeberle D, Betticher DC, von Moos R, Dietrich D, Brauchli P, Baertschi D, et al. Bevacizumab continuation versus no continuation after first-line chemotherapy plus bevacizumab in patients with metastatic colorectal cancer: a randomized phase III non-inferiority trial (SAKK 41/06). *Ann Oncol*. 2015 Apr;26(4):709–14.
- 17 Lee JJ, Kim TM, Yu SJ, Kim DW, Joh YH, Oh DY, et al. Single-agent capecitabine in patients with metastatic colorectal cancer refractory to 5-fluorouracil/leucovorin chemotherapy. *Jpn J Clin Oncol*. 2004 Jul;34(7):400–4.
- 18 Tebbutt NC, Wilson K, GebSKI VJ, Cummins MM, Zannino D, van Hazel GA, et al. Capecitabine, bevacizumab, and mitomycin in first-line treatment of metastatic colorectal cancer: results of the Australasian Gastrointestinal Trials Group Randomized Phase III MAX Study. *J Clin Oncol*. 2010 Jul 1;28(19):3191–8.
- 19 Cunningham D, Lang I, Marcuello E, Lorusso V, Ocivirk J, Shin DB, et al. Bevacizumab plus capecitabine versus capecitabine alone in elderly patients with previously untreated metastatic colorectal cancer (AVEX): an open-label, randomised phase 3 trial. *Lancet Oncol*. 2013 Oct;14(11):1077–85.
- 20 Marcus L, Lemery SJ, Keegan P, Pazdur R. FDA approval summary: pembrolizumab for the treatment of microsatellite instability-high solid tumors. *Clin Cancer Res*. 2019 Jul 1;25(13):3753–8.
- 21 Golshani G, Zhang Y. Advances in immunotherapy for colorectal cancer: a review. *Therap Adv Gastroenterol*. 2020 Jun 1;13:1756284820917527.
- 22 Santoni M, Rizzo A, Mollica V, Matrana MR, Rosellini M, Faloppi L, et al. The impact of gender on the efficacy of immune checkpoint inhibitors in cancer patients: the MOUSEION-01 study. *Crit Rev Oncol Hematol*. 2022 Feb;170:103596.
- 23 Santoni M, Rizzo A, Kucharz J, Mollica V, Rosellini M, Marchetti A, et al. Complete remissions following immunotherapy or immuno-oncology combinations in cancer patients: the MOUSEION-03 meta-analysis. *Cancer Immunol Immunother*. 2023 Jun;72(6):1365–79.