

Case Report

Personalized Treatment Approach to Metastatic Castration-Resistant Prostate Cancer with BRCA2 and PTEN Mutations: A Case Report

Pramod Kumar Julka^a Amit Verma^a Kush Gupta^b

^aMax Institute of Cancer Care, New Delhi, India; ^bCatalyst Clinical Services Pvt. Ltd., New Delhi, India

Keywords

CRPC · BRCA2 · PTEN · Olaparib · Prostate cancer

Abstract

DNA repair mutations (BRCA1 and BRCA2) are found in metastatic castration-resistant prostate cancer (CRPC) patients. Here, we report a case of a 71-year-old male patient with metastatic CRPC along with BRCA2 and PTEN mutations. As per the genomic findings of the Foundation One report, FDA-approved therapies were available for other tumor types, such as olaparib for the loss of BRCA2 and everolimus for the loss of PTEN exons 2–9. These findings were confirmed in another novel phenotypic assay that revealed the sensitivity of olaparib and carboplatin combination therapy. After 4 cycles, our patient achieved a partial response along with a good performance status.

© 2020 The Author(s)
Published by S. Karger AG, Basel

Introduction

Prostate cancer is the second most common cancer among men worldwide, with an incidence of 1.3 million in 2018 [1]. It is also the fifth leading cause of cancer deaths among men [1]. Androgen deprivation therapy with or without docetaxel is the recommended first-line treatment modality for the management of metastatic hormone-naïve disease [2]. In chemotherapy-naïve patients with metastatic castration-resistant prostate cancer (CRPC), abiraterone or enzalutamide is the recommended treatment option [3]. Docetaxel is recommended for patients with metastatic CRPC, whereas radium-223 is recommended for those

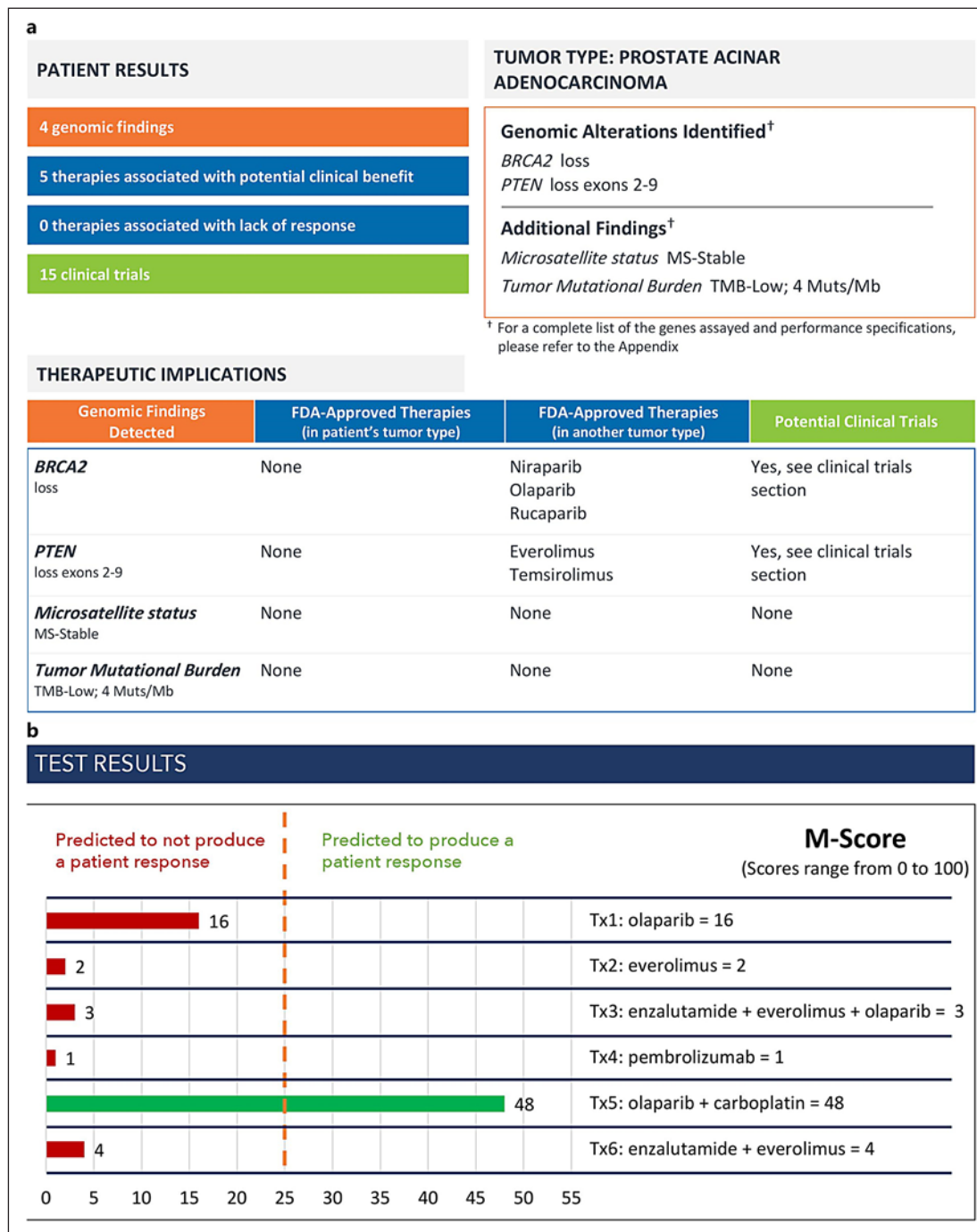
Dr. Pramod Kumar Julka
Max Institute of Cancer Care
Lajpat Nagar
New Delhi 110024 (India)
pkjulka18@yahoo.co.in

without visceral disease [4]. The second-line treatment strategies for patients with metastatic CRPC after docetaxel include abiraterone, enzalutamide, cabazitaxel, and radium-223 [5–7]. Prostate cancer is a heterogeneous disease at both the clinical and molecular level; however, its treatment strategies have not yet been molecularly stratified. The 2019 National Comprehensive Cancer Network Clinical Practice Guidelines in Oncology for prostate cancer recommend germline testing for homologous recombination genes (BRCA1, BRCA2, ATM, PALB2, and CHEK2) using next-generation sequencing (NGS) [8]. DNA repair mutations (BRCA1 and BRCA2) are found in metastatic CRPC lesions that are resistant to taxane and may respond well to platinum and poly-(ADP-ribose)-polymerase inhibitors, such as olaparib [9]. Here, we report the first case of metastatic CRPC with BRCA2 and PTEN mutations which was successfully treated with olaparib and carboplatin combination therapy.

Case Presentation

A 71-year-old hypertensive male patient presented with complaints of heaviness in the lower abdomen in April 2017. His general condition was good (Eastern Cooperative Oncology Group performance status of 1). His clinical workup included a prostate-specific antigen (PSA) assay and a contrast-enhanced computed tomography scan of the chest and the entire abdomen. The findings of the contrast-enhanced computed tomography scan were suggestive of an enlarged prostate with a focal area of hyperdensity in the right lobe, metastatic deposits in the lumbar spine and bilateral lung parenchyma, and small peri-pancreatic, pre-aortic, and para-aortic lymph nodes. The patient had an elevated PSA level of 101 ng/ml. A metastatic workup was performed via prostate-specific membrane antigen (PSMA) positron emission tomography CT (PET-CT) that showed a slightly increased PSMA uptake in the prostate gland (maximum standardized uptake value, 7.7) along with multiple PSMA-avid lung lesions of variable sizes (with the largest measuring 1.4 × 1.0 cm); subcarinal and right external iliac lymph nodes measuring 1.4 × 1.1 cm and 1.9 × 1.5 cm, respectively; and multiple sclerotic skeletal lesions. Transrectal ultrasound-guided biopsy revealed a poorly differentiated adenocarcinoma of the prostate, a Gleason score of 10, perineural invasion, angioinvasion, and the absence of neuroendocrine features.

The patient received two subcutaneous injections of goserelin (a gonadotropin-releasing hormone agonist) 3 months apart (10.8 mg in April and July 2017). The PSA levels in July and October 2017 were 19.25 and 89 ng/mL, respectively. Due to the increasing PSA level, the patient was started on abiraterone acetate (1,000 mg), prednisolone, and zoledronic acid. A PSMA PET-CT scan performed in October 2017 showed an increase in PSMA avidity in the skeletal lesions, and the patient was scheduled for external beam radiotherapy to the right iliac crest and sacral region using the stereotactic body radiotherapy technique. After radiotherapy, the PSA level remained elevated (111.72 ng/mL); thus, the patient was started on single-agent chemotherapy with docetaxel (50 mg/m² every 2 weeks) in November 2017. The patient responded well to docetaxel therapy, and the PSA level reduced significantly to 9 ng/mL in December 2017. The patient completed 9 cycles of docetaxel until April 2018 and continued to receive abiraterone acetate, prednisolone, and zoledronic acid. The PSA level started to increase again (to 35.48 ng/mL) in April 2018, and a PSMA PET-CT scan performed to evaluate the disease status revealed that the disease was stable. The PSA level continued to increase progressively in the subsequent months with values of 123.98, 142.10, and 203.71 ng/mL, respectively. The PSMA PET-CT scan was repeated in August 2018 and showed disease progression (enlargement of the existing lesions and new lesions in the lung and liver). The patient was started on enzalutamide (160 mg) with a plan for NGS-based genomic profiling using Foundation One (Roche Products Pvt. Ltd., Mumbai, India).



Predicted to not produce a patient response

Predicted to produce a patient response

M-Score
(Scores range from 0 to 100)

16		Tx1: olaparib = 16
2		Tx2: everolimus = 2
3		Tx3: enzalutamide + everolimus + olaparib = 3
1		Tx4: pembrolizumab = 1
48		Tx5: olaparib + carboplatin = 48
4		Tx6: enzalutamide + everolimus = 4

0 5 10 15 20 25 30 35 40 45 50 55

Fig. 1. a The Foundation One report of the patient. **b** Sensitivity test results with the M score of each of the six treatment arms.

The Foundation One report revealed loss of *BRCA2* and *PTEN* exons 2–9 with stable microsatellite status and low tumor mutational burden (Fig. 1a). As per the Foundation One report, there was no Food and Drug Administration (FDA)-approved therapy for the patient’s tumor type. However, there were FDA-approved therapies for the genomic findings detected for other tumor types, such as niraparib, olaparib, and rucaparib for the loss of *BRCA2* and evero-

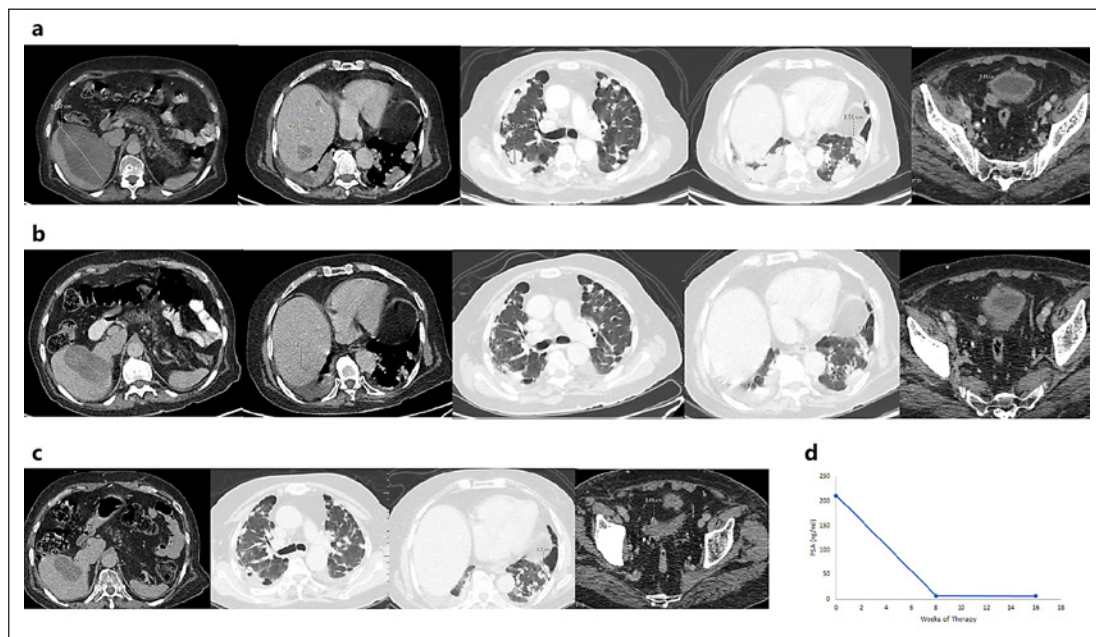


Fig. 2 **a** Baseline PSMA PET-CT images. **b** PSMA PET-CT images after 2 cycles of olaparib and carboplatin therapy. **c** PSMA PET-CT images after 4 cycles of olaparib and carboplatin therapy. **d** PSA level at baseline and after 8 and 16 weeks of therapy. PSMA PET-CT, prostate-specific membrane antigen positron emission tomography computed tomography; PSA, prostate-specific antigen.

limus and temsirolimus for the loss of PTEN exons 2–9. Since no FDA-approved therapies could be found, we decided to perform another novel phenotypic multidimensional assay that tests the patient's tumor tissue against different drug combinations in an ex-vivo implant setting to help us select the most appropriate treatment protocol for this patient. The test could predict the response to either single-agent cancer therapeutics or combination therapeutic regimens for the patient under evaluation. This was accomplished using a fresh tumor tissue sample obtained from the patient in plates coated with a specific set of tumor matrix proteins. Further, patient-derived autologous ligands were added to the explant platform along with angiogenic factors and autologous immune cells to maintain the tumor vasculature. Essentially, the test recapitulated the tumor microenvironment ex vivo. The sensitivity test was performed as per the priority list of treatment protocols decided by the treating physician. The option with the highest assigned priority (Tx1) was considered as the physician's preferred choice. The test used a proprietary algorithm to generate an M score (0–100), with a score of ≤ 25 indicating predicted non-response and > 26 indicating predicted response [10]. Six treatment arms were tested: Tx1 (olaparib), Tx2 (everolimus), Tx3 (enzalutamide + everolimus + olaparib), Tx4 (pembrolizumab), Tx5 (olaparib + carboplatin), and Tx6 (enzalutamide + everolimus), and the M score ranged between 1 and 48 (Fig. 1b). While the olaparib and everolimus arms indicated non-response with M scores of 16 and 2, respectively, Tx5 (olaparib + carboplatin) was the arm that indicated response with the highest M score of 48.

Based on the clinical judgment of the molecular tumor board, a choice of combination therapy was made, and the patient was started on low dose olaparib (200 mg twice daily) and carboplatin (AUC 2 – D1, D8, and D15 every 28 days) combination chemotherapy (Tx5) in September 2018. Before starting the olaparib and carboplatin combination therapy, a baseline PSMA PET-CT scan revealed five target lesions with an overall tumor burden of 207.6 mm (Fig. 2a). The PSA level at this time was 211.23 ng/mL (Fig. 2d) with an Eastern Cooperative

Oncology Group performance status of 3. After 2 cycles, the PSMA PET-CT scan demonstrated a partial response (36.3% reduction from baseline, overall tumor burden of 132.2 mm) as per the Response Evaluation Criteria in Solid Tumors version 1.1 (Fig. 2b). The PSA level at that time was 6.8 ng/mL (Fig. 2d). For the first time, the patient responded to treatment, and there were no associated grade 3/4 toxicities. After 4 cycles, the PSMA PET-CT scan revealed further regression (55.3% reduction from baseline) with an overall tumor burden of 92.8 mm along with complete regression of the lesion in the right hepatic lobe (Fig. 2c). The PSA level at that time was 5.99 ng/mL (Fig. 2d), and the performance status also improved to 1. After 4 cycles, the patient migrated to another country where he received 2 more treatment cycles. Currently, the patient is alive with a good performance status 9 months after initiation of olaparib and carboplatin combination therapy.

Discussion/Conclusion

Homologous repair deficiency (HRD) genes (particularly BRCA1/2) are found in 20–25% of all patients with metastatic CRPC [11]. Although the 2019 National Comprehensive Cancer Network guidelines recommend germline testing for all prostate cancer patients, treatment based on molecular characterization is still not commonly practiced [8]. Even if germline or somatic mutation testing reveals BRCA1/2 mutations, there is currently no FDA-approved therapy for the treatment of this subset of patients with metastatic CRPC. The poly-(ADP-ribose)-polymerase inhibitor olaparib is known to have a significant synthetic lethal effect on tumors with BRCA1/2 mutations, particularly in ovarian and breast cancer [12]. Although there are few reports in the literature on the role of olaparib in the treatment of metastatic CRPC with DNA-repair defects, the combination of olaparib and carboplatin has never been studied earlier for this indication. We used the olaparib and carboplatin combination therapy based on two facts. First, HRD genes are known to be sensitive to platinum. Second, sensitivity testing confirmed that the patient would respond to olaparib and carboplatin (M score of 48) but not to olaparib or everolimus monotherapy (M scores of 16 and 2, respectively).

In a phase 2 study conducted by Mateo et al. [13], NGS revealed mutations in BRCA1/2, ATM, Fanconi's anemia genes, and CHEK2 in 16 out of 49 patients with metastatic CRPC. Treatment with olaparib (400 mg twice daily) demonstrated a very good response rate of 88% (the biomarker suite had a specificity of 94%). The study revealed a significantly longer median progression-free survival period (9.8 vs. 2.7 months, $p < 0.001$) and median overall survival period (13.8 vs. 7.5 months, $p = 0.05$) in the biomarker-positive group as compared to the biomarker-negative group. The partial response achieved in our case corroborates the findings of this study. In the study conducted by Mateo et al. [13], 7 patients had loss of BRCA2 (4 cases of biallelic somatic loss and 3 cases of germline mutations), and all 7 responded to olaparib therapy. While 5 patients achieved partial response radiologically, the PSA level decreased by $\geq 50\%$ from baseline in all 7 patients with BRCA2 loss. The 36.3 and 55.3% reductions in tumor burden after cycles 2 and 4, respectively, as well as the $>96\%$ reduction in PSA level observed in our patient suggest that olaparib and carboplatin combination therapy is superior to single-agent olaparib in this patient subset. The 9-month progression-free survival in our case is also in line with the findings of Mateo et al. [13].

Ma et al. [14] reported the response of a 67-year-old patient with metastatic CRPC carrying a BRCA2 germline mutation to olaparib. Although the patient showed a partial response after 2 months, the disease progressed after 6 months. Another phase 2 study conducted by Kaufman et al. [15] evaluated the efficacy and safety of olaparib in different malignant solid tumors with confirmed genetic BRCA1/2 mutation. Of the 298 patients enrolled in the study, 7 had metastatic CRPC with BRCA2 mutation. The study yielded an

overall response rate of 50% with median progression-free and overall survival durations of 7.2 and 18.4 months, respectively. These results are consistent with our observations; however, our patient had only been followed up for 9 months at the time of writing this report.

So far, olaparib and carboplatin combination therapy has never been studied among CRPC patients; we report the first case on this chemotherapy and targeted therapy combination. This case demonstrates the clinical utility of olaparib and carboplatin combination therapy in patients with metastatic CRPC with BRCA2 loss. Further, the good partial response achieved in this case establishes the importance of germline testing for homologous recombination genes (BRCA1, BRCA2, ATM, PALB2, and CHEK2) using NGS among patients with metastatic CRPC.

Olaparib and carboplatin combination therapy holds promise for the management of metastatic CRPC patients with BRCA2 loss. The administration of olaparib and carboplatin combination therapy can demonstrate a good response along with prolonged survival in patients with metastatic CRPC associated with DNA-repair defects.

Statement of Ethics

The subject has given his written informed consent to publish this case (including publication of images). The study protocol was approved by the institute's Committee on Human Research.

Disclosure Statement

The authors declare that there are no competing interests.

Funding Sources

Nil.

Author Contributions

Pramod Kumar Julka was responsible for the conception and design of this paper, acquisition of data, analysis and interpretation of data, drafting the article and final approval of the version to be published. Amit Verma and Kush Gupta were responsible for drafting the article and final approval of the version to be published.

References

- 1 Bray F, Ferlay J, Soerjomataram I, Siegel RL, Torre LA, Jemal A. Global cancer statistics 2018: GLOBOCAN estimates of incidence and mortality worldwide for 36 cancers in 185 countries. *CA Cancer J Clin*. 2018 Nov;68(6):394–424.
- 2 Parker C, Gillessen S, Heidenreich A, Horwich A; ESMO Guidelines Committee. Cancer of the prostate: ESMO Clinical Practice Guidelines for diagnosis, treatment and follow-up. *Ann Oncol*. 2015 Sep;26(Suppl 5):v69–v77.
- 3 Ryan CJ, Smith MR, Fizazi K, Saad F, Mulders PF, Sternberg CN, et al; COU-AA-302 Investigators. Abiraterone acetate plus prednisone versus placebo plus prednisone in chemotherapy-naïve men with metastatic castration resistant prostate cancer (COU-AA-302): final overall survival analysis of a randomised, double-blind, placebo-controlled phase 3 study. *Lancet Oncol*. 2015 Feb;16(2):152–60.

- 4 Tannock IF, de Wit R, Berry WR, Horti J, Pluzanska A, Chi KN, et al; TAX 327 Investigators. Docetaxel plus prednisone or mitoxantrone plus prednisone for advanced prostate cancer. *N Engl J Med*. 2004 Oct;351(15):1502–12.
- 5 de Bono JS, Oudard S, Ozguroglu M, Hansen S, Machiels JP, Kocak I, et al; TROPIC Investigators. Prednisone plus cabazitaxel or mitoxantrone for metastatic castration-resistant prostate cancer progressing after docetaxel treatment: a randomised open-label trial. *Lancet*. 2010 Oct;376(9747):1147–54.
- 6 de Bono JS, Logothetis CJ, Molina A, Fizazi K, North S, Chu L, et al; COU-AA-301 Investigators. Abiraterone and increased survival in metastatic prostate cancer. *N Engl J Med*. 2011 May;364(21):1995–2005.
- 7 Scher HI, Fizazi K, Saad F, Taplin ME, Sternberg CN, Miller K, et al; AFFIRM Investigators. Increased survival with enzalutamide in prostate cancer after chemotherapy. *N Engl J Med*. 2012 Sep;367(13):1187–97.
- 8 Mohler JL, Antonarakis ES. NCCN guidelines updates: management of prostate cancer. *J Natl Compr Canc Netw*. 2019 May;17(5.5):583–6.
- 9 Fong PC, Boss DS, Yap TA, Tutt A, Wu P, Mergui-Roelvink M, et al. Inhibition of poly(ADP-ribose) polymerase in tumors from BRCA mutation carriers. *N Engl J Med*. 2009 Jul;361(2):123–34.
- 10 Majumder B, Baraneedharan U, Thiyagarajan S, Radhakrishnan P, Narasimhan H, Dhandapani M, et al. Predicting clinical response to anticancer drugs using an ex vivo platform that captures tumour heterogeneity. *Nat Commun*. 2015 Feb;6:6169.
- 11 Marshall CH, Fu W, Wang H, Baras AS, Lotan TL, Antonarakis ES. Prevalence of DNA repair gene mutations in localized prostate cancer according to clinical and pathologic features: association of Gleason score and tumor stage. *Prostate Cancer Prostatic Dis*. 2019 Mar;22(1):59–65.
- 12 Ledermann J, Harter P, Gourley C, Friedlander M, Vergote I, Rustin G, et al. Olaparib maintenance therapy in platinum-sensitive relapsed ovarian cancer. *N Engl J Med*. 2012;366:1382–92.
- 13 Mateo J, Carreira S, Sandhu S, Miranda S, Mossop H, Perez-Lopez R, et al. DNA-repair defects and olaparib in metastatic prostate cancer. *N Engl J Med*. 2015;373(18):1697–708.
- 14 Ma Y, He L, Huang Q, Zheng S, Zhang Z, Li H, et al. Response to olaparib in metastatic castration-resistant prostate cancer with germline BRCA2 mutation: a case report. *BMC Med Genet*. 2018 Oct 17;19(1):185.
- 15 Kaufman B, Shapira-Frommer R, Schmutzler RK, Audeh MW, Friedlander M, Balmaña J, et al. Olaparib monotherapy in patients with advanced cancer and a germline BRCA1/2 mutation. *J Clin Oncol*. 2015;33(3):244–50.